

# Hemodynamic Evaluation Using esCCO during Cesarean Section under Spinal Anesthesia

Department of Anesthesiology, Osaka Women's and Children's Hospital, Osaka, Japan



**Yuki Nakano, MD**

Deputy Director, Department of Anesthesiology, Osaka Women's and Children's Hospital, Osaka, Japan



**Jun Takeshita, MD, PhD**

Chief Director, Department of Anesthesiology, Osaka Women's and Children's Hospital, Osaka, Japan



**Kazuya Tachibana, MD, PhD**

Estimated continuous cardiac output (esCCO) is a new parameter to estimate and continuously display cardiac output (CO) and stroke volume (SV) using the electrocardiogram (ECG), blood pressure (BP)\*, and a dedicated pulse oximeter. \*Either invasive or non-invasive measurements of BP may be used.

We experienced a case of cesarean section under spinal anesthesia with esCCO monitoring.

## Background

In cesarean section under spinal anesthesia, maternal hypotension is likely to occur after the initiation of anesthesia.

Rapid fluid infusion or vasopressor administration is performed with frequent non-invasive blood pressure monitoring to maintain uteroplacental blood flow. However, there are limited reports of observing continuous changes of CO after the initiation of anesthesia.

esCCO is a non-invasive continuous CO monitor that uses the negative correlation between SV and pulse wave transit time (PWTT), which is determined by the time from the R-wave of the ECG to the start of the pulse oximeter wave and provides continuous display of hemodynamic changes. This report describes our experience of hemodynamic management with esCCO monitoring during a cesarean section under spinal anesthesia in a pregnant woman with severe obesity.

## Case

A 33-year-old primiparous woman with a height of 164 cm and a body weight of 107 kg had concurrent hypertensive disorders of pregnancy, severe obesity (BMI of 39.8 kg/m<sup>2</sup>), and type 2 diabetes. An attempt was made to induce delivery due to pregnancy-induced hypertension at 37 weeks and 6 days of gestation, but failed. Thus, she underwent urgent cesarean section under spinal anesthesia. Immediately before the initiation of anesthesia, BP was 166/96 mmHg, heart rate (HR) was 114 bpm, and esCCO was 10.9 L/min. After the initiation of anesthesia, the operating table was positioned left-tilt and head-down with the patient in the supine position, and crystalloid solution was rapidly infused. After that, BP was 90/52 mmHg, HR was 86 bpm, and esCCO was 8.04 L/min. 0.2 mg of phenylephrine was administered as an intravenous bolus twice. After that, BP was 131/52 mmHg, HR was 67 bpm, and esCCO was 6.33 L/min. After an adequate anesthetic block height was obtained, the operating table was returned to its original horizontal position. After that, BP was 79/41 mmHg, HR was 72 bpm, and esCCO was 6.29 L/min. Uterine left displacement, rapid infusion of crystalloid solution, and a bolus of 0.2 mg of phenylephrine led to BP of 121/79 mmHg, HR of 83 bpm, and esCCO of 7.86 L/min (Figure 1).

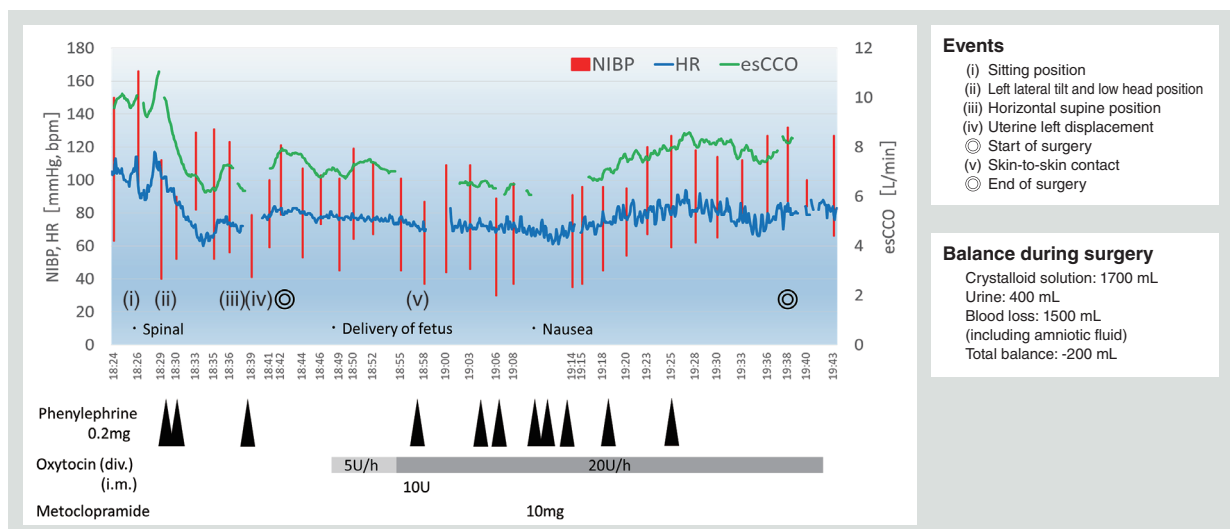


Figure 1 esCCO monitoring in an urgent cesarean section under spinal anesthesia

## Discussion

esCCO decreased after the initiation of anesthesia, but administration of phenylephrine did not always increase esCCO. Phenylephrine decreases HR due to baroreceptor reflex and may contribute to a decrease in CO.<sup>1</sup> During the course of pregnancy, decreased maternal CO and increased peripheral vascular resistance are associated with reduced uteroplacental blood flow and fetal growth restriction.<sup>2,3</sup> Therefore, anesthetic management to maintain CO during cesarean section may also be necessary.

After delivery of the fetus, decreases in esCCO caused by oxytocin and bleeding were observed, possibly coinciding in time with nausea. However, such a coincidence is not known for certain because there were errors in the esCCO measurement due to body movement-related noise in the ECG or the pulse oximeter. In addition, esCCO requires approximately three minutes of rest for initial calibration. This may be unsuitable depending on the degree of urgency of surgery (Figure 2).

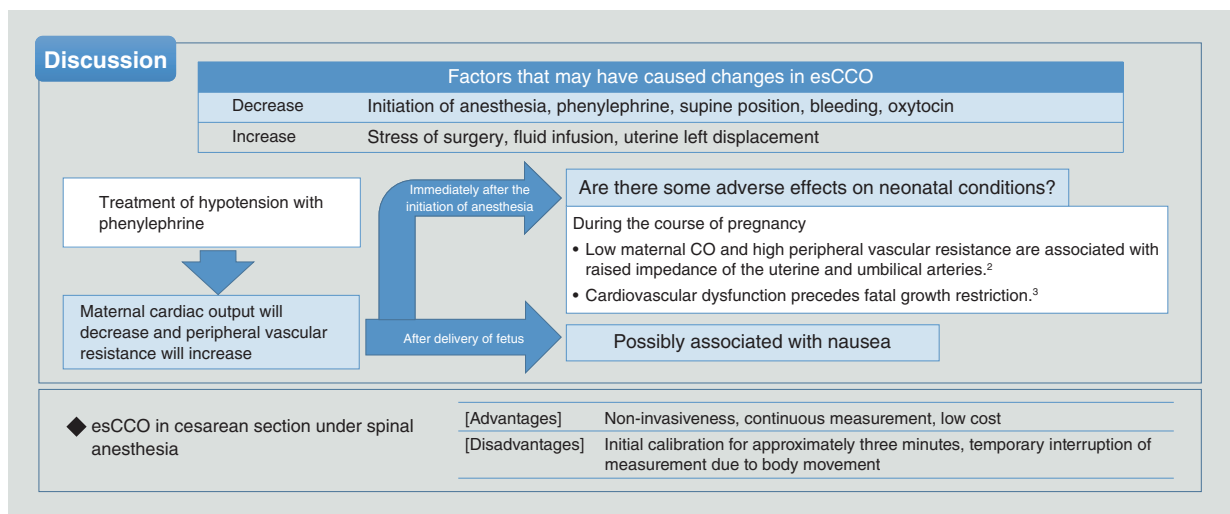


Figure 2 Discussion of esCCO in an urgent cesarean section under spinal anesthesia

## Future expectations

The use of esCCO in clinical practice of cesarean sections provided us continuous information on dynamic changes, and we got a view that had not been seen with hemodynamic management relying on previous non-invasive BP monitoring. Visualization of changes in esCCO in the absence of blood pressure measurements may facilitate smooth responses to hypotension and provide safer anesthesia for mothers and infants.

In addition, an approach to hemodynamic management targeted at maintaining CO requires not only phenylephrine but also several alternatives, such as fluid infusion and noradrenaline, and esCCO may play a role in assessing these alternatives. The greatest advantage of esCCO is that we can monitor cardiac output with a combination of ECG, BP and a dedicated pulse oximeter. In contrast, we expect further technological improvements to ameliorate the disadvantages of initial calibration time and sensitivity to body movement.

## Overall comment

It is important for anesthetic management to supply adequate blood flow and oxygen to tissues and organs. Even if BP is maintained, oxygen supply might not be assured. We have been using ECG, BP and SpO<sub>2</sub> as independent parameters. However, esCCO will be a breakthrough parameter that provides non-invasive and continuously useful information for anesthetic management by combining these parameters.

<Kazuya Tachibana, Chief Director, Department of Anesthesiology>

## References

1. Dyer RA, et al. "Spinal hypotension during elective cesarean delivery: closer to a solution." *Anesth Analg* Nov 2010; 111(5):1093-5.
2. Stampalija T, et al. "The Association of First Trimester Uterine Arteries Doppler Velocimetry With Different Clinical Phenotypes of Hypertensive Disorders of Pregnancy: A Longitudinal Study." *J Matern Fetal Neonatal Med* Apr 2017; 32 (7), 1191-1199.
3. Tay J, et al. "Uterine and Fetal Placental Doppler Indices Are Associated With Maternal Cardiovascular Function." *Am J Obstet Gynecol* Jan 2019; 220 (1), 96.e1-96.e8

This material is a summary of the presentation given at the 123rd Annual Meeting of the Japan Society for Obstetric Anesthesia and Perinatology with permission of the Japan Society for Obstetric Anesthesia and Perinatology.